



SLIMS,PONDICHERRY



Date 06/05/18

From

DR.R.CHIDHAMBARAM ,
Professor and Head,
Dept.of radio-diagnosis and Imaging Sciences ,
SLIMS,PONDICHERRY
Bharath Institute of Higher Education and Research,
Chennai.

To

The Dean,
SLIMS
Bharath Institute of Higher Education and Research,
Chennai.

Sub: Permission to conduct value-added course:

BASIC ABDOMINAL X-RAY INTERPRETATION

Dear Sir,

With reference to the subject mentioned above, the department proposes to conduct a value-added course titled:-**BASIC ABDOMINAL X-RAY INTERPRETATION** on 06/05/18. We solicit your kind permission for the same.

Kind Regards

DR.R.CHIDHAMBARAM

FOR THE USE OF DEANS OFFICE

Names of Committee members for evaluating the course:

The Dean: *Dr. S. Jayaraman*

The HOD: *Dr. R. Chidhambaram*

The Expert: *Dr. J. J. Jeyaraj*

The committee has discussed about the course and is approved.

Dean

Subject Expert

HOD

(Sign & Seal)

(Sign & Seal)

(Sign & Seal)

DEAN

BIHER
Bharath Institute of Higher Education and Research,
Chennai, Anna Salai, Madurai,
K. S. Nagar, K. S. Nagar,
Chennai, Tamil Nadu, India

SLIMS

Course Proposal

Course Title: BASIC ABDOMINAL X-RAY INTERPRETATION

Course Objective: TO DEMONSTRATE BASIC ABDOMINAL X-RAY INTERPRETATION

Course Outcome: BETTER UNDERSTANDING OF BASIC ABDOMINAL X-RAY INTERPRETATION

Course Audience: ANY MEDICAL STUDENT

Course Coordinator: PROF.DR.R.CHIDHAMBARAM

Course Faculties with Qualification and Designation:

1. DR.R.CHIDHAMBARAM,MBBS,MDRD.PROF. AND HOD
2. DR.SIVASHIRRAMANTYAN,MBBS,DNB,ASST PROFESSOR
3. DR.JYOTI BASU,MBBS,DNB,SENIOR RESIDENT

Course Curriculum/Topics with schedule (Min of 30 hours)-ENCLOSED

S/No	Date	Topic	Time	Hours
1	03-01-2018	INTRO	2:00 PM	2 HOUR
2	04-01-2018	INDICATIONS	2:00 PM	2 HOUR
3	05-01-2018	Patient preparation	2:00 PM	2 hour
4	06-01-2018	TECHNIQUE	2:00 PM	2 HOUR
5	07-01-2018	POSITIONING	2:00 PM	2 HOUR
6	08-01-2018	VIEWS	2:00 PM	2 HOUR
7	09-01-2018	QUALITY CHECK	2:00 PM	2 HOUR
8	10-01-2018	STANDARD VIEW	2:00 PM	2 HOUR
9	11-01-2018	RADIOGRAPHIC ANATOMY-1	2:00 PM	2 HOUR
10	12-01-2018	RADIOGRAPHIC ANATOMY-2	2:00 PM	2 HOUR
11	13-01-2018	RADIOGRAPHIC ANATOMY-3	2:00 PM	2 HOUR
12	14-01-2018	Rad.densities	2:00 PM	2 HOUR
13	15-01-2018	Basic Interpretation-1	2:00 PM	2 HOUR
14	16-01-2018	Basic Interpretation-2	2:00 PM	2 HOUR
15	17-01-2018	Basic Interpretation-3	2:00 PM	2 HOUR
			Total Hours	30

BIHER

SLIMS



OFFICE OF THE DEAN

Sri Lakshmi Narayana Institute of Medical Sciences

OSUDU, AGARAM VILLAGE, VILLIANUR COMMUNE, KUDAPAKKAM POST,
PUDUCHERRY - 605 502.

[Recognised by Medical Council of India, Ministry of Health letter No. U112012/249/2005-ME; P-II) dL 11/07/2011]
[Affiliated to Bharath University, Chennai - TN]

Circular

19.05.2018

Sub: Organising Value-added Course, BASIC ABDOMINAL X-RAY INTERPRETATION
reg

With reference to the above mentioned subject, it is to bring to your notice that Sri Lakshmi Narayana Institute of Medical Sciences, **Bharath Institute of Higher Education and Research** is organizing "**BASIC ABDOMINAL X-RAY INTERPRETATION**". The course content and registration form is enclosed below."

The application must reach the institution along with all the necessary documents as mentioned. The hard copy of the application should be sent to the institution by registered/ speed post only so as to reach on or before May to June 2018. Applications received after the mentioned date shall not be entertained under any circumstances.

Dean

Encl: Copy of Course content

19/05/2018
SRI LAKSHMI NARAYANA INSTITUTE OF MEDICAL SCIENCES
OSUDU, AGARAM VILLAGE,
VILLIANUR COMMUNE,
KUDAPAKKAM POST - 605 502

BIHER

SLIMS

VALUE ADDED COURSE

1. Name of the programme & Code :

**Abdominal x ray interpretation
RAD 07**

2. Duration & Period

30 hrs & September 2018– January 2019 & February2019 – August 2019

3. Information Brochure and Course Content of Value Added Courses

Enclosed as Annexure- I

4. List of students enrolled

Enclosed as Annexure- II

5. Assessment procedures:

Multiple choice questions- *Enclosed as Annexure- III*

6. Certificate model

Enclosed as Annexure- IV

7. No. of times offered during the same year:

September 2018– January 2019 & February2019 – August 2019

8. Year of discontinuation: 2019

9. Summary report of each program year-wise

Value Added Course- September 18 - August 19					
Sl. No	Course Code	Course Name	Resource Persons	Target Students	Strength & Year
1	RAD 07-1	Abdominal xray interpretation	Dr.Jothibasu	MBBS	20 (Sep 18 Jan 19)
2	RAD 07-2	Abdominal xray interpretation	Dr.Sivasubramaniyan	MBBS	20 (Feb18- Aug-19)

10. Course Feed Back

Enclosed as Annexure- V


RESOURCE PERSON

BIHER


COORDINATOR

SLIMS




Sri Lakshmi Narayana Institute of Medical Sciences



சென்னை மாநகராட்சி மருத்துவமனை

This is to certify that SHENHA has actively participated in the Value Added Course on **BASICS OF ABDOMINAL XRAY INTERPRETATION** held during September 2018- January 2019 Organized by Sri Lakshmi Narayana Institute of Medical Sciences, Pondicherry-605 002, India


Dr. T. Koushik
RESOURCE PERSON


Dr. R. Chidambaram
CO-ORDINATOR




Sri Lakshmi Narayana Institute of Medical Sciences



சென்னை மாநகராட்சி மருத்துவமனை

This is to certify that **RAJAKANDRAN** has actively participated in the Value Added Course on **BASICS OF ABDOMINAL XRAY INTERPRETATION** held during February 2019 - August 2019 Organized by Sri Lakshmi Narayana Institute of Medical Sciences, Pondicherry-605 002, India.


Dr. M. Elvasudramaniyan
RESOURCE PERSON


Dr. S. Chidambaram
CO-ORDINATOR

BIHER

SLIMS

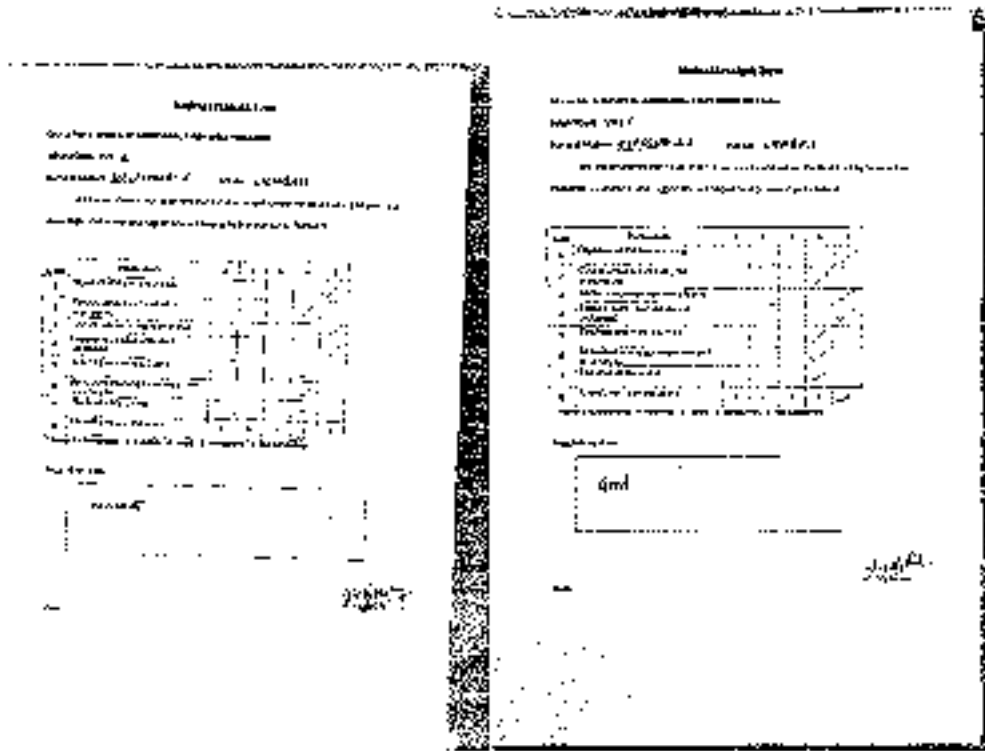
TOPIC: Value Added Course
Basics of Microeconomics & its application
 List of Students Enrolled

BT YEAR WISE STUDENTS			
S.NO	NAME OF THE STUDENT	UNIVERSITY REG. NO	SIGNATURE
1	SAKSHI INDRAN SUDARSHAN	U26N0315	
2	SHIKHA SINGH	U16H0376	
3	SINGARSETTY SARDAR	U16H0377	
4	SINGARSETTY SRIHAR	U26N0370	
5	SNEHA	U16H0379	
6	SNEHA SINGH	U26N0380	
7	RIKHA VERMA	U16H0382	
8	RYSHI AGRWAL	U26N0384	
9	ROHITSHIKHU KESHU	U16H0385	
10	RYANULLA YASIN MUKHAMMAD	U26H0386	
11	PARTHASARATHY S	U16H0387	
12	RITIKA VERMA	U16H0388	
13	RUHI PADMINI HARAYAN	U26N0396	
14	RAMITSHA PALLI	U16H0397	
15	RAMHARSHAN LK	U16H0398	
16	RAHMA TA J	U16H0399	
17	RAHSHIKA S	U16H0400	
18	RISHI YAGGI NARAYAN	U16H0401	
19	RAKESHIA PALLEI	U16H0402	
20	ASMITHA S	U26H0407	
21	RISHI VENKATA SAIKISHAN	U16H0408	
22	ARJUN PACTHIA	U16H0409	
23	RAJACHANDRAN	U16H0410	
24	RAJAN S	U16H0411	
25	RISHI KARAN K.C	U16H0412	
26	RISHI KARAN K.C	U16H0413	
27	RAJESH PURAN KESHU SURESH	U16H0414	
28	ROHIT PALLI	U16H0415	
29	LUKESHYALAKH V	U16H0416	
30	RAHSHI KARAN K	U16H0417	
	RESOURCE PERSON		
			COORDINATOR



BIHER

SLIMS



BIHER

SLIMS

1. A 46-year-old man presents with acute large bowel obstruction, rectal bleeding, and change in bowel habit. What is the most likely cause?

- A) Inguinal hernia B) Adenoma C) Colitis D) Haemorrhoids E) Polypoid carcinoma

2. A 65-year-old woman presents with irregular periods and menorrhagia. She has had an hysterectomy 20 years ago. Small bowel intussusception is observed. What is the most likely cause?

- A) Inguinal hernia B) Adenoma C) Polypoid carcinoma D) Haemorrhoids E) Leiomyosarcoma

3. A 65-year-old woman presents with 10 years of vomiting. On the 4th day of admission an abdominal radiograph shows the most the presence of large abdominal mass?

- A) Inguinal hernia B) Adenoma C) Polypoid carcinoma D) Leiomyosarcoma E) Colon carcinoma

4. A 50-year-old female with long-standing rheumatoid arthritis. A CT scan of the pelvis shows a large pelvic mass. What is the most likely diagnosis?

- A) Large ovarian teratoma B) Fibrous chondroma C) Leiomyosarcoma D) Leiomyoma E) Fibrous tissue damage to the uterus

5. An elderly female is referred for a pelvic ultrasound of the uterus. What is the following piece of clinical information a contraindication to scan?

- A) History of previous pelvic surgery B) History of previous hysterectomy C) History of previous pelvic surgery D) History of previous hysterectomy

6. A 65-year-old woman presents with acute large bowel obstruction, rectal bleeding and change in bowel habit. What is the most likely cause?

10. A 65-year-old male presents with a 2-week history of weight loss and decreased appetite. He has a 40-pack-year smoking history. What is the most likely cause of his symptoms?

A) Gastric cancer B) Adenocarcinoma C) Squamous cell carcinoma D) Pancreatic cancer E) Colorectal cancer

11. A 65-year-old male presents with a 2-week history of weight loss and decreased appetite. He has a 40-pack-year smoking history. What is the most likely cause of his symptoms?

A) Gastric cancer B) Adenocarcinoma C) Squamous cell carcinoma D) Pancreatic cancer E) Colorectal cancer

12. A 65-year-old male presents with a 2-week history of weight loss and decreased appetite. He has a 40-pack-year smoking history. What is the most likely cause of his symptoms?

A) Gastric cancer B) Adenocarcinoma C) Squamous cell carcinoma D) Pancreatic cancer E) Colorectal cancer

13. An MRI of the brain is requested for a patient suspected of having a brain tumor. Which of the following pieces of clinical information is a contraindication to MRI?

A) Metal hip replacement B) History of previous seizures C) Renal insufficiency D) Contrast allergy E) Claustrophobia

BIHER

SLIMS

Date: 06/05/18

From

Dr.R.Chidambaram
Professor and Head,
Department of Microbiology,
Sri Lakshmi Narayana Institute of Medical Sciences
Bharath Institute of Higher Education and Research,
Chennai.

Through Proper

Channel

To

The Dean,
Sri Lakshmi Narayana Institute of Medical Sciences
Bharath Institute of Higher Education and Research,
Chennai.

Sub- Completion of value-added course: **BASIC ABDOMINAL X-RAY INTERPRETATION**


Dear Sir,

With reference to the subject mentioned above, the department has conducted the value-added course titled: : **BASIC ABDOMINAL X-RAY INTERPRETATION** for 20 medical students (batch 2).

We solicit your kind action to send certificates for the participants, that is attached with this letter. Also, I am attaching the photographs captured during the conduct of the course.

Kind Regards,

Dr R.Chidambaram



Encl: Certificates

Photographs

SRI LAKSHMI NARAYANA

INSTITUTE OF MEDICAL SCIENCES

DEPARTMENT OF RADIOLOGY AND IMAGING SCIENCES

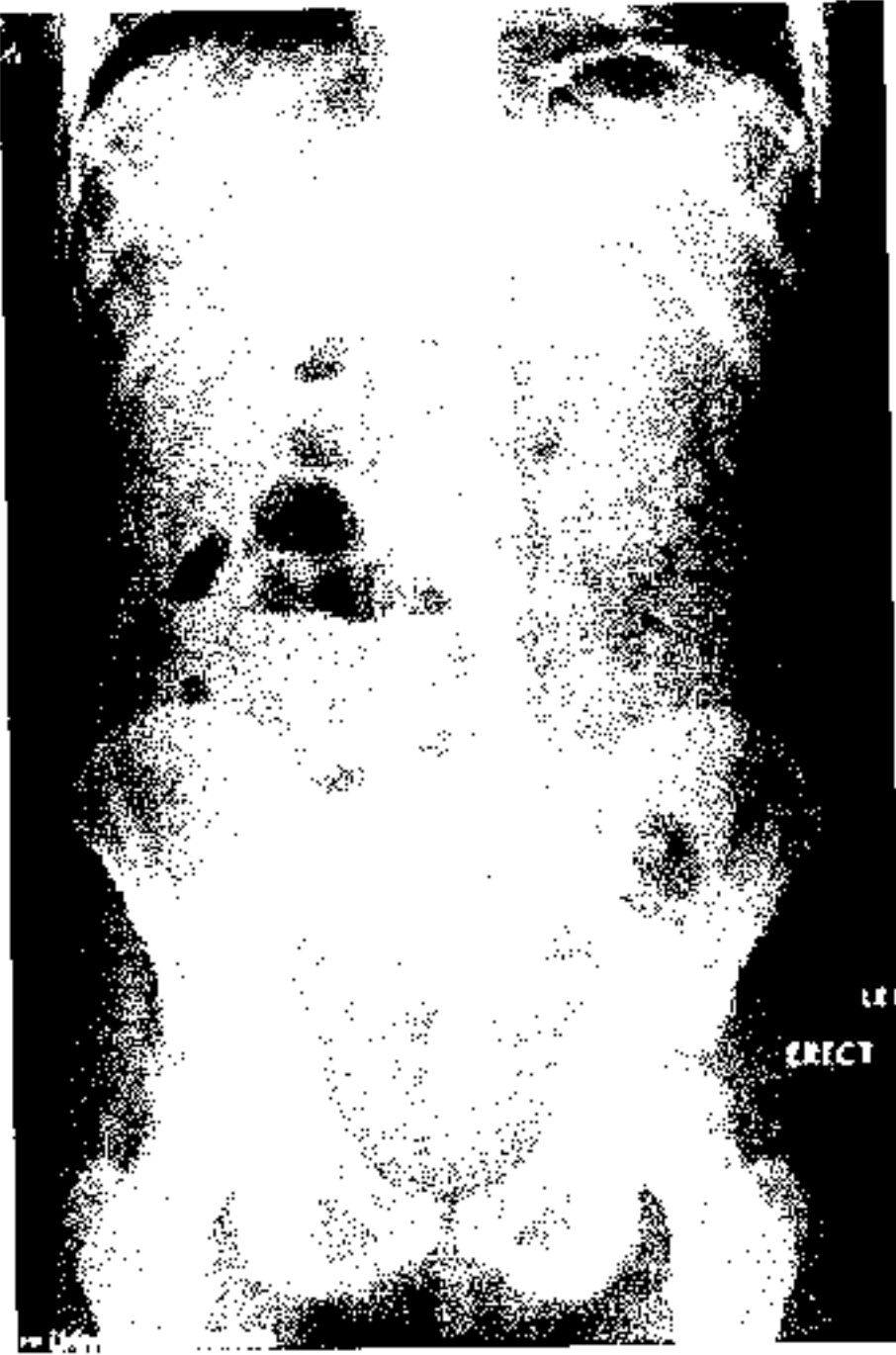
BASIC OF ABDOMINAL X-RAY INTERPRETATION

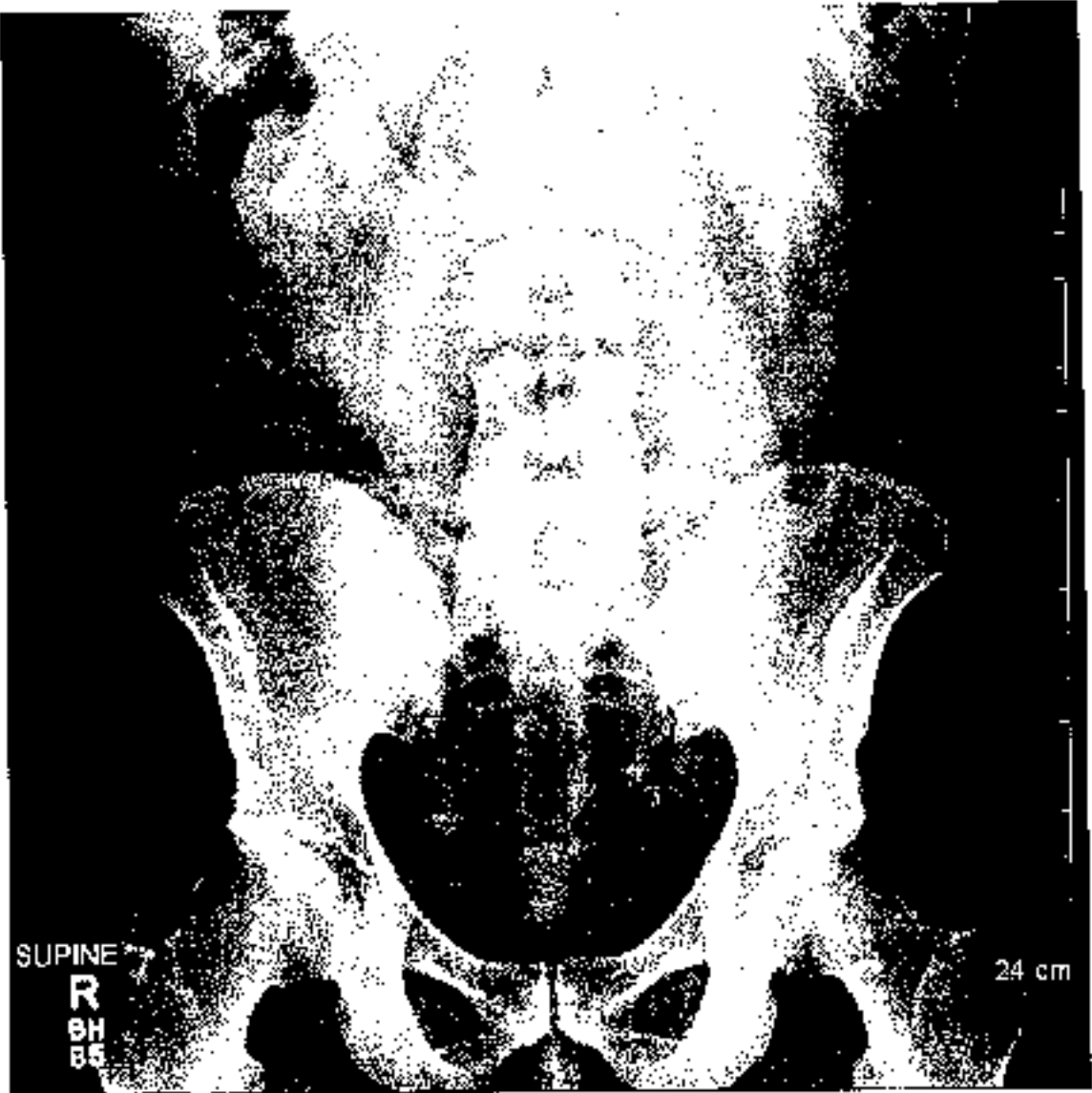COURSE CONTENT

Basic Views

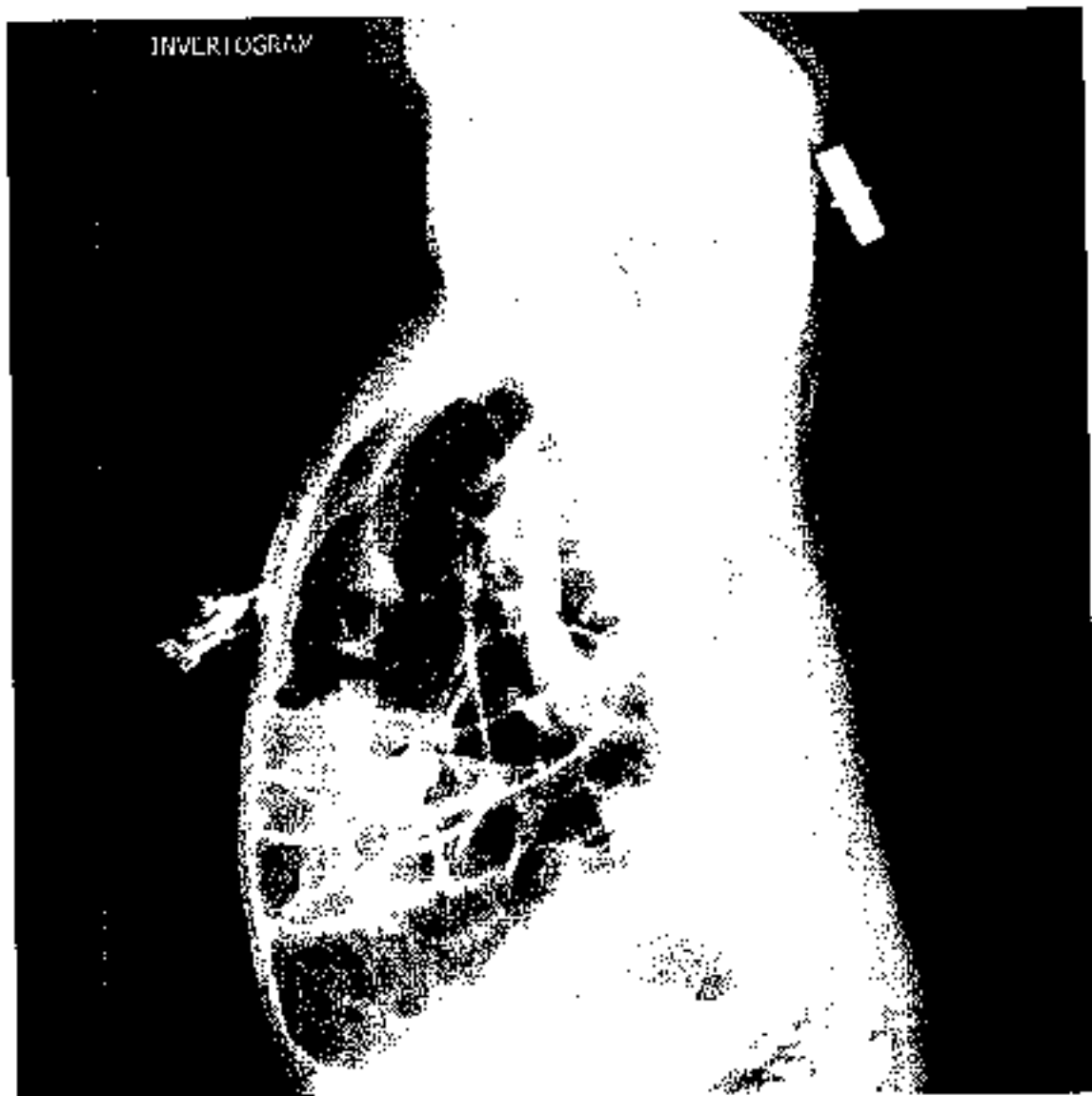
Assessing the quality of film

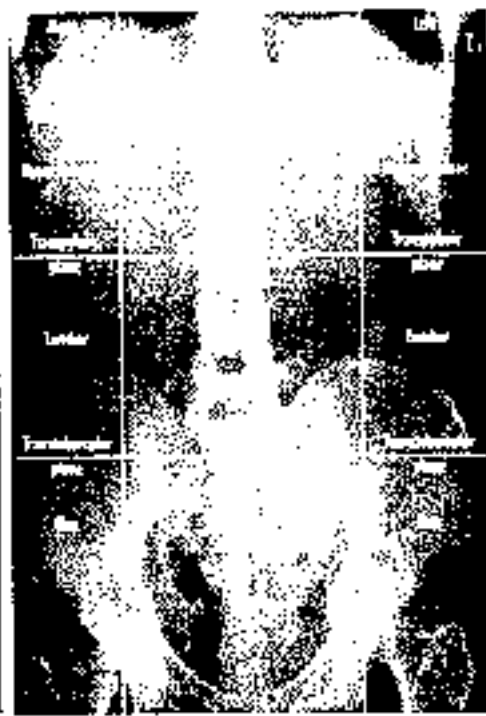
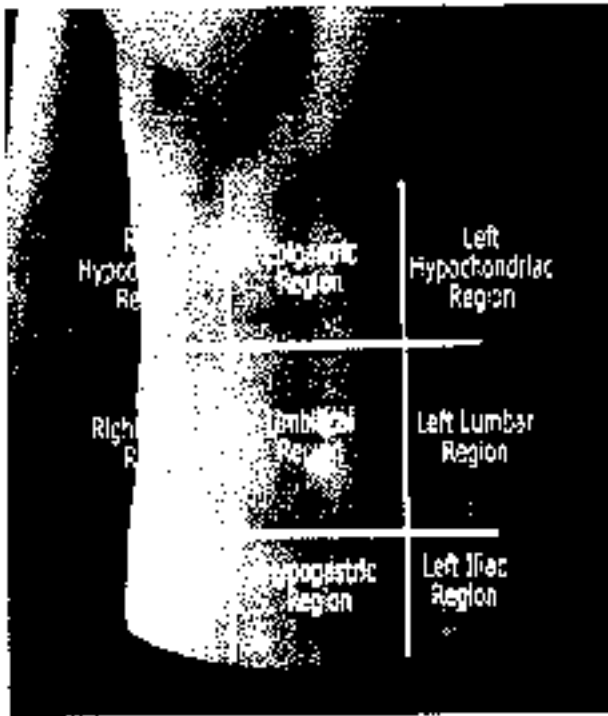
Identifying normal structures





INVERTOGRAM





01/11/2023

01/11/2023 11:20:03 AM

5

VENUE:

LECTURE HALL :II

TIME : SAT 2 TO 4 PM.