



Date-20-11-2018

From
Dr. K. Harsha Vardhan
Professor and Head,
Department of Dermatology,
Sri Lakshmi Narayana Institute of Medical Sciences
Bharath Institute of Higher Education and Research,
Chennai.

To
The Dean
Sri Lakshmi Narayana Institute of Medical Sciences
Bharath Institute of Higher Education and Research,
Chennai.

Sub: Permission to conduct value-added course: Onychomycosis

Dear Sir,

With reference to the subject mentioned above, the department proposes to conduct a value-added course titled: **Onychomycosis** on 20-12-2018 . We solicit your kind permission for the same.

Kind Regards

Dr. K. Harsha Vardhan

FOR THE USE OF DEANS OFFICE

Names of Committee members for evaluating the course:

The Dean: Dr. A. Sugumaran

The HOD: Dr. K. Harsha Vardhan

The Expert: Dr. A. Buvanaratchagan

The committee has discussed about the course and is approved.

DEAN
SRI LAKSHMI NARAYANA INSTITUTE OF MEDICAL SCIENCES
OSUDU, AGARAM VILLAGE,
KODAPAKKAM POST,
PUDUCHERRY - 605 502

Subject Expert

HOD



Date-20-11-2018

From
Dr. K. Harsha Vardhan
Professor and Head,
Department of Dermatology,
Sri Lakshmi Narayana Institute of Medical Sciences
Bharath Institute of Higher Education and Research,
Chennai.

To
The Dean
Sri Lakshmi Narayana Institute of Medical Sciences
Bharath Institute of Higher Education and Research,
Chennai.

Sub: Permission to conduct value-added course: Onychomycosis

Dear Sir,

With reference to the subject mentioned above, the department proposes to conduct a value-added course titled: **Onychomycosis** on 20-12-2018 . We solicit your kind permission for the same.

Kind Regards

Dr. K. Harsha Vardhan

FOR THE USE OF DEANS OFFICE

Names of Committee members for evaluating the course:

The Dean: Dr. A. Sugumaran

The HOD: Dr. K. Harsha Vardhan

The Expert: Dr. A. Buvanaratchagan

The committee has discussed about the course and is approved.

DEAN
SRI LAKSHMI NARAYANA INSTITUTE OF MEDICAL SCIENCES
OSUDU, AGARAM VILLAGE,
KOODAPAKKAM POST,
PUDUCHERRY - 605 502

Dr. A. BUVANARATCHAGAN, MD.,
Reg. No: 37150
Asso. Professor, Dermatology
Sri Lakshmi Narayana Institute of Medical Sciences
Osudu, Agaram Village, Puducherry-605 502

Subject Expert

PROFESSOR & HEAD
DEPT. OF DERMATOLOGY
SRI LAKSHMI NARAYANA INSTITUTE OF
MEDICAL SCIENCES
OSUDU, PUDUCHERRY.
HOD



OFFICE OF THE DEAN

Sri Lakshmi Narayana Institute of Medical Sciences

OSUDU, AGARAM VILLAGE, VILLIANUR COMMUNE, KUDAPAKKAM POST,
PUDUCHERRY - 605 502.

[Recognised by Medical Council of India, Ministry of Health letter No. U/12012/249/2005-ME (P -II) dt. 11/07/2011]
[Affiliated to Bharath University, Chennai - TN]

Circular

27.11.2018

Sub: Organising Value-added Course: Onychomycosis (Nov 2018 – Feb- 2019)

With reference to the above mentioned subject, it is to bring to your notice that Sri Lakshmi Narayana Institute of Medical Sciences, **Bharath Institute of Higher Education and Research** is organizing "**Onychomycosis**". The course content is enclosed below."

The hard copy of the application should be sent to the institution by registered/ speed post only so as to reach on or before 13-12-2018. Applications received after the mentioned date shall not be entertained under any circumstances.

DEAN
SRI LAKSHMI NARAYANA INSTITUTE OF MEDICAL SCIENCES
OSUDU, AGARAM VILLAGE,
KODAPAKKAM POST,
PUDUCHERRY - 605 502

Encl: Copy of Course content

Course Proposal

Course Title: Onychomycosis
Course Objective: To evaluate predisposing factors and treatment of onychomycosis
Course Outcome: Completed
Course Audience: second year mbbs students
Course Coordinator: Dr. K. Harsha Vardhan
Course Faculties with Qualification and Designation:
1. Dr. K. Harsha Vardhan
Professor , Department of Dermatology
2. Dr. Buvanaratchagan
Associate Professor, Department of Dermatology

Course Curriculum/Topics with schedule (Min of 30 hours)

Sl No	Date	Topic	Time	Hours	Lecture taken by
1	20-12-18	Introduction	5 to 7 pm	2hours	. Dr. K. Harsha Vardhan
2	24-12-18	Etiology	4:30 to 6:30 pm	2hours	Dr. Buvanaratchagan
3	28-12-18	Predisposing factors	4 to 6 pm	2hours	Dr. K. Harsha Vardhan
4	2-1-19	Types	5 to 7 pm	2hours	Dr. Buvanaratchagan
5	4-1-19	Variants	4:30 to 6:30 pm	2hours	Dr. K. Harsha Vardhan
6	9-1-19	Investigation	4 to 6 pm	2hours	Dr. Buvanaratchagan
7	14-1-19	Topical treatment	5 to 7 pm	2hours	Dr. K. Harsha Vardhan
8	17-1-19	Systemic treatment	4:30 to 6:30 pm	2hours	Dr. Buvanaratchagan
9	21-1-19	Complications	4 to 6 pm	2hours	Dr. K. Harsha Vardhan
10	24-1-19	Other treatment methods	4 to 6 pm	2hours	Dr. K. Harsha Vardhan
11	29-1-19	Case discussion	5 to 7 pm	2hours	Dr. Buvanaratchagan
12	4-2-19	Onychomycosis in Immunocompromised	4:30 to 6:30 pm	2hours	Dr. K. Harsha Vardhan
13	8-2-19	Pulse therapy for onychomycosis	4 to 6 pm	2hours	Dr. Buvanaratchagan
14	13-2-19	Guidelines for pulse therapy	5 to 7 pm	2hours	Dr. K. Harsha Vardhan
15	20-2-19	Q&A, mcqs	4:30 to 6:30 pm	2hours	Dr. Buvanaratchagan
			Total Hours	30	

REFERENCE BOOKS:

Rooks Textbook of dermatology 9th edition

Fitzpatrick 's dermatology in general medicine 8th edition

ABSTRACT-VALUE ADDED COURSE

1. Name of the programme & Code

Onychomycosis and DR09

2. Duration & Period

30 hrs & November 2018 to February 2019

3. Information Brochure and Course Content of Value Added Courses

Enclosed as Annexure- I

4. List of students enrolled

Enclosed as Annexure- II

5. Assessment procedures:

Multiple choice questions- *Enclosed as Annexure- III*

6. Course Feed Back

Enclosed as Annexure- IV

7. No. of times offered during the same

November 2018 to February 2019

8. Year of discontinuation: 2019

9. Summary report of each program year-wise

Value Added Course- November 2018 to February 2019					
Sl. No	Course Code	Course Name	Resource Persons	Target Students	Strength & Year
1	DR09	Onychomycosis	Dr. Buvanaratchagan	2nd yr MBBS	15 (Nov 2018– Feb 19)

10. Certificate model

Enclosed as Annexure- V

Dr. Buvanaratchagan

Dr. K. Harsha Vardhan

RESOURCE PERSON

COORDINATOR

ABSTRACT-VALUE ADDED COURSE

1. Name of the programme & Code

Onychomycosis and DR09

2. Duration & Period

30 hrs & November 2018 to February 2019

3. Information Brochure and Course Content of Value Added Courses

Enclosed as Annexure- I

4. List of students enrolled

Enclosed as Annexure- II

5. Assessment procedures:

Multiple choice questions- *Enclosed as Annexure- III*

6. Course Feed Back

Enclosed as Annexure- IV

7. No. of times offered during the same

November 2018 to February 2019

8. Year of discontinuation: 2019


9. Summary report of each program year-wise

Value Added Course- November 2018 to February 2019					
Sl. No	Course Code	Course Name	Resource Persons	Target Students	Strength & Year
1	DR09	Onychomycosis	Dr. Buvanaratchagan	2nd yr MBBS	15 (Nov 2018 Feb 19)

10. Certificate model

Enclosed as Annexure- V

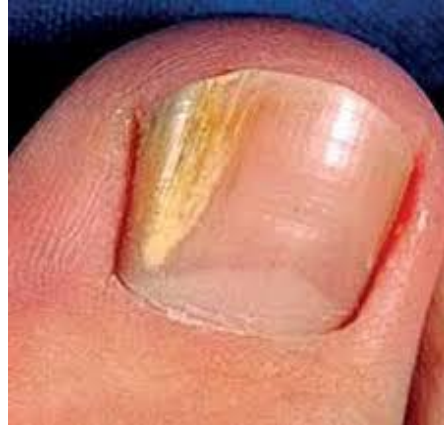Dr. Buvanaratchagan


RESOURCE PERSON
DR. A. BUVANARATCHAGAN, MD.,
Reg. No: 37150
Asso. Professor, Dermatology
Sri Lakshmi Narayana Institute of Medical Sciences
Osudu, Kudalankem, Puducherry-605 502.


Dr. K. Harsha Vardhan
PROFESSOR & HEAD
DEPT. OF DERMATOLOGY
SRI LAKSHMI NARAYANA INSTITUTE OF
MEDICAL SCIENCES
OSUDU, PUDUCHERRY
COORDINATOR

ANNEXURE-1

ONYCHOMYCOSIS



PARTICIPANT HAND BOOK

Course details

PARTICULARS	DESCRIPTION
Course title	Onychomycosis
Course code	DR09
Objective	<ol style="list-style-type: none">1. To learn about the clinical features2. To learn about the diagnosis3. To learn about the treatment
Further learning opportunities	Recent advances in management
Key competencies	To make the diagnosis and provide adequate treatment
Target student	2 nd year mbbs students
Duration	30 hrs Nov 2018 to Feb 2019
Theory session	10 hrs
Practical session	20 hrs
Assessment procedure	Mcqs

Introduction

Onychomycosis is a fungal infection of nails caused by dermatophytes, yeasts or nondermatophyte molds and represents about 30% of mycotic cutaneous infections. Increasingly onychomycosis is being viewed as more than a mere cosmetic problem. In spite of improved personal hygiene and living environment, onychomycosis continues to spread and persist. The prevalence rate of onychomycosis is determined by age, predisposing factor, social class, occupation, climate, living environment and frequency of travel. Onychomycosis in immunocompromised patients can pose a more serious health problem. Dermatophytes are the most frequently implicated causative agents in onychomycosis. Previously regarded as contaminants, yeasts are now increasingly recognised as pathogens in fingernail infections, as are some moulds. Clinical diagnosis of onychomycosis is based on the patients' history; a physical examination, microscopy and culture of nail specimens. The treatment of onychomycosis has been attempted throughout the ages, but only in the last two decades have safe, effective systemic treatments been available for this chronic superficial fungal disease. Oral Griseofulvin and Ketoconazole; once the agents of choice for the treatment of onychomycosis, have been

superseded by newer systemic compounds that have a higher cure and lower relapse rates, cause fewer side effects and are suitable for short-term dosing.

Until the late 1990s onychomycosis was a poorly discussed topic of medical science. Even in financially more advanced Asian countries, onychomycosis has been highlighted only in the last decade. Onychomycosis is a denomination used to describe fungal infection of one or more of the nail units and can be caused by dermatophytes, yeasts or nondermatophyte moulds.^[1] Onychomycosis affects approximately 5% of the population worldwide^[2] and represents 20-40% of onychopathies and about 30% of mycotic cutaneous infections.^[3] Various workers have reported the incidence to vary from 0.5 to 5% in the general population in India.^{[4],[5]} In developing countries, higher priorities in socioeconomic concerns and health issues for other diseases, have resulted in low awareness of onychomycosis by physicians and the general public alike. In spite of improved personal hygiene and living environment, onychomycosis continues to spread and persist. Though there is a clearly diseased appearance associated with this condition, onychomycosis is all too often regarded as merely a cosmetic problem of relatively minor importance that is hardly worth the effort to seek treatment in many cases. This belief may have been supported by the adverse effects and long dosing courses associated with some of the earlier antifungal agents. Only in the last two decades have safe, effective systemic treatment regimens been available for this chronic superficial fungal disease that can have significant negative effects on patients' emotional, social and occupational functioning. Although onychomycosis is rarely life threatening, its high incidence and prevalence and the associated morbidity makes it an important public health problem. In this paper, current knowledge of the pathogenesis, diagnosis and management of onychomycosis is reviewed.

Epidemiology and risk factors

Reports concerning the prevalence of onychomycosis are conflicting with estimates ranging from 2-3% to 13% in the western population.^{[6],[7]} Unlike in western countries where it is the frequent cause of nail disorders, in Southeast Asia the prevalence of onychomycosis is relatively low. This was partially confirmed by a large scale-survey in Asia in the late 1990s in which the prevalence of onychomycosis was lower in tropical countries (3.8%) than in subtropical countries and the countries in the temperate zone (18%).^[8] In India, the prevalence of fungal nail infections has been estimated in the different parts of the country and the observations are listed in [Table - 1]. The prevalence rate of onychomycosis is determined by age, predisposing factor, social class, occupation, climate, living environment and frequency of travel.^[9] The prevalence is higher (25%) in patients with human immunodeficiency virus infection (HIV).^[10] Several studies have shown that prevalence of onychomycosis increases with age, reasons for which may include poor peripheral circulation, diabetes, repeated nail trauma, longer exposure to pathogenic fungi, sub optimal immune function, inactivity or the inability to cut the toe nails or maintain good foot care.^[7] As is the case among adults, prevalence rates for onychomycosis among children are quite variable: a recent review of studies of the subject in several countries lists

prevalence rates varying from 0% (United states, Wales and Finland) to 2.6% (Guatemala). The reasons for this 30-fold decrease in the prevalence of onychomycosis in children relative to adults may include reduced exposure to fungus because less time is spent in environments containing pathogens; faster nail growth, smaller nail surface for invasion and lower prevalence of tinea pedis [Figure - 1].^[11] However, the worldwide prevalence of onychomycosis is increasing. In one study that evaluated the prevalence and risk factors of onychomycosis in individuals representing different strata of population in New Delhi the prevalence of onychomycosis was confirmed in 45% of the analysed patients.^[12] A number of factors may contribute to this rise. First, as the population ages, there is a corresponding increase in chronic health problems (diabetes) and poor peripheral circulation. Second, the number of persons who are immunocompromised because of infections with human immunodeficiency virus and the use of immunosuppressive therapy, cancer chemotherapy or antibiotics, continue to expand. Third, avid sports participation is increasing the use of health clubs, commercial swimming pools and occlusive foot wears for exercise.^[13] In a small percentage of persons, onychomycosis may be caused by a genetic defect that causes an alteration in immune function.^[14] Contact with the source of the infection constitutes a risk factor. Other factors that increase the risk of onychomycosis are direct trauma to the nail including nail biting. Onychomycosis in immunocompromised patients can pose a more serious health problem. Not only does the difficult-to-treat infection serve as a constant reminder to the patient of his or her own deteriorated condition, the possibility exists of transfer of fungal pathogens to other individuals.^[13]

Definition, etiology and classification

Onychomycosis has been traditionally referred to a non-dermatophytic infection of the nail but is now used as a general term to denote all fungal infections of the nail. Tinea unguium specifically describes a dermatophyte invasion of the nail. The term onychomycosis is derived from the Greek word "onyx", a nail and "mykes" a fungus. Toenails are about 25 times more likely than fingernails to be infected. The longest toe, either the first or the second, which bears the brunt of pressure and trauma from footwear, is particularly susceptible to invasion, although multiple nails are typically infected [Figure - 2].

Dermatophytes are the most frequently implicated causative agents in onychomycosis (nearly 90% in toenail and at least 50% in fingernail infections). Previously regarded as contaminants, yeasts are now increasingly recognized as pathogens in fingernail infections, as are some moulds.^[15] The incidence and clinical significance of other than dermatophytic fungi or moulds causing onychomycosis is not well known, because they may be colonising organisms rather than pathogens. The rates of isolation of various fungi in onychomycosis are listed in [Table - 2]. One report, which presented the results of a two-year study, conducted to determine the incidence and aetiology of onychomycosis by nondermatophytic fungi in the population of Spain, described a number of species, such as *Fusarium* spp., *Scytalidium* spp. and *Acremonium* spp. etc. as aetiological agents of onychomycosis.^[16] Nondermatophyte moulds cause 1.5-6% of onychomycosis.^[17] Onychomycosis secondary to nondermatophyte moulds is seen most frequently in the elderly, in patients with skin diseases that affect the nails and in immunocompromised patients. It is more frequent in toes than in fingers. Many of these fungi

are highly sensitive to cycloheximide and may be missed if the specimen is not also inoculated on a cycloheximide-free medium, such as Sabouraud glucose agar, Littman's Oxgall agar or potato dextrose agar. Clinical clues that a nondermatophyte mould is the causative pathogen may include the absence of tinea pedis, only one or two infected toenails, a history of trauma, a history of nonresponsiveness to systemic antimycotics and association with periungual inflammation.

There are three groups of fungi associated with onychomycosis: dermatophytes, non-dermatophytic moulds and yeasts.

Common fungal agents causing Onychomycosis

1. Dermatophytes:

Trichophyton rubrum

Trichophyton mentagrophytes

Epidermophyton floccosum

2. Nondermatophyte fungi:

Acremonium species

Alternaria species

Aspergillus species

Botryodiplodia theobromae

Fusarium species

Onychochola canadensis

Scytalidium dimidiatum

Scytalidium hyalinum

Geotrichum candidum

Cladosporium carrionii

Scopulariopsis brevicaulis

3. Yeast:

Candida albicans

CLINICAL FEATURES

Distal subungual onychomycosis

The most common variety of onychomycosis, distal lateral subungual onychomycosis (DLSO), is characterised by invasion of the nail bed and underside of the nail plate. It is best described as "nail bed dermatophytosis". The infecting organism migrates proximally through the underlying nail matrix. Mild inflammation develops, resulting in focal parakeratosis and subungual hyperkeratosis, with two consequences: onycholysis and subungual thickening. The nail bed becomes cornified and normal nail contour is lost. The thickened horny layer raises the free edge of the nail plate with disruption of the nail plate to nail bed attachment. DSO may develop on the fingernails, toenails or both. The dermatophytes predominate as causative agents with occasional involvement of the non-dermatophyte fungi. The commonest species of dermatophytes causing this type of onychomycosis is *T. rubrum* followed by *T. mentagrophytes*, *T. tonsurans* and *E. floccosum*. The ideal site for collection of specimen in DLSO is nail bed underside of the nail plate from the advancing edge, most proximal to the cuticle. DLSO may progress to total dystrophic onychomycosis in which case the entire nail plate and bed are involved.

Proximal subungual onychomycosis

This is also known as proximal white subungual onychomycosis (PWSO) or proximal subungual onychomycosis (PSO). A relatively uncommon subtype, PSO occurs when organisms invade the nail unit via the proximal nail fold through the cuticle area, penetrate the newly formed nail plate and migrate distally resulting in subungual hyperkeratosis, proximal onycholysis, leukonychia and destruction of the proximal nail plate. Fungal invasion of the proximal nail fold is often visible through the cuticle as a whitish yellow discolouration while the distal nail unit remains normal. Periungual inflammation may be quite marked and painful and in some cases associated with purulent discharge. These patients are frequently misdiagnosed as having bacterial infection. It affects the fingernails and toenails equally and is primarily caused by *T. rubrum*; though *T. mentagrophytes* and other rare causes have also been reported to cause this condition. PSO has been described with increased frequency in patients with acquired immunodeficiency syndrome (AIDS).^[18] Toenails involvement is more common and *T. rubrum* is the most common

pathogen. The explanation for the increased prevalence in this patient population remains unclear. The specimen is taken from nail plate and proximal nail bed as close to lunula as possible. Subungual hyperkeratosis, onychomadesis and eventual destruction and shedding of the entire nail plate may occur in advanced disease.

White superficial onychomycosis

White superficial onychomycosis (WSO) ; a less common variety, is a distinctive pattern in which the nail plate is the primary site of invasion. This is the surface infection of the nail primarily when the fungi invade the superficial layers of the nail plate directly and is caused by *T. mentagrophytes* and sometimes by the nondermatophyte molds like *Acremonium* spp., *Aspergillus terreus* and *Fusarium oxysporum* . It can be recognized by the presence of well-delineated opaque "white islands" on the external nail plate, which coalesce and spread as the disease progresses resulting in a rough, soft and crumbly appearance of the nail. Inflammation is usually minimal in patients with WSO because viable tissue is not involved. WSO occurs primarily in toenails. It may also be found in patients of acquired immunodeficiency syndrome. The surface scrapings of the nail plate are the ideal specimens to demonstrate the fungi.

Candida onychomycosis

Candida nail infections occur in patients with chronic mucocutaneous candidiasis and are caused by *C. albicans* in 70% of cases of onychomycosis caused by the yeast; *C. parapsilosis* , *C. tropicalis* and *C. krusei* account for the remainder of the cases. ^[19] Both toenails and fingernails may be involved [Figure - 3]. The organism invades the nail plate directly and has three subtypes:

Candida paronychia: This is the most common type and is marked by swelling and erythema of the proximal and lateral nail folds, also called a "whitlow". After infection of the nail matrix occurs, transverse depressions (Beau's lines) may appear in the nail plate, which becomes convex, irregular and rough and ultimately dystrophic.

Candida granuloma: This type is uncommon and is characterised by direct invasion and thickening of the nail plate and associated paronychia. This condition is seen in immunocompromised patients. The organism may affect the entire thickness of the nail, resulting in advanced cases, in swelling of the proximal and lateral nail folds until the digit develops a pseudo clubbing or "chicken drumstick" appearance. It is useful to take sample from both the nail plates as well as the subungual debris of the infected nail.

Candida onycholysis: This occurs when the nail plate separates from the nail bed. Distal subungual hyperkeratosis can be seen as a yellowish grey mass lifting off the nail plate. The lesion resembles that seen in patients with DSO.

Total dystrophic onychomycosis (TDO) : In this type there is total destruction of the nail plate, which usually may be the end result of the any of the four main patterns of onychomycosis. The

entire nail unit becomes thick and dystrophic. TDO is used to describe end-stage nail disease, although some clinicians consider it a distinct subtype [Figure - 4].

DIAGNOSIS

Increasingly onychomycosis is being viewed as more than a mere cosmetic problem. Persons with unsightly infected nails may suffer embarrassment. Fungi from the nails may precipitate secondary bacterial infections, cellulitis, idiopathic reactions and chronic urticaria. Infected toenails may act as a reservoir for fungi, facilitating their transmission to other areas of the body and may even to other people.

Clinical diagnosis of onychomycosis is based on the patients' history; a physical examination, microscopy and culture of nail specimens. Predisposing factors like diabetes, old age, hyperhidrosis, onychoglyphosis, nail trauma, poor peripheral circulation are likely to be present. Several nail disorders that may mimic fungal nail infections must be differentiated from one another and onychomycosis to initiate the most appropriate therapy. They include psoriasis, lichen planus, bacterial infections, contact dermatitis, traumatic onychodystrophies, paronychia congenital, nail bed tumours, yellow-nail syndrome, idiopathic onycholysis etc.

One should look for cutaneous signs of psoriasis on the scalp, gluteal folds, elbows and knees and nails should be evaluated for other signs of psoriasis, especially for pitting and/or small salmon coloured droplets evident on the plate. Approximately 10% of patients with lichen planus have abnormal nails. [2],[4] A practitioner can differentiate lichen planus by looking for the violaceous purple papules ridged/dystrophic nail indicative of lichen planus on the extremities or by other signs on the mucous membranes. Repeated nail trauma can cause distal onycholysis, leading to colonization of the affected space by microorganisms that produce pigmentation of the area. If the onycholytic nail is clipped to allow examination of the nail bed, the latter will be normal if the symptoms are caused by trauma rather than onychomycosis. A habit tic, often manifesting as a median furrow or depression in the middle of the nail, may also cause abnormalities of the nail. The yellow nail syndrome may also be mistaken for a fungal infection; however, the hardness of the nail plate, its increased longitudinal curvature and the light green/yellow discoloration are all typical and discriminatory.

Specimen collection

A proper specimen collection is essential for accurate diagnosis and initiation of appropriate therapy. The first step of the sample collection process is thorough cleansing of the nail area with alcohol to remove contaminants. Because the sites of invasion and localisation of the infection differ in the different types of onychomycosis, different approaches depending on the presumptive diagnosis are necessary to obtain optimal specimens.

For distal subungual onychomycosis, the abnormal nail is clipped proximally and the nail bed

and underside of the nail plate are scraped with a 1-2 mm serrated curette; the outermost debris should be discarded. Care should be taken to avoid penetration of the nail plate and bleeding. It is important to obtain nail material from the advancing infected edge closest to the cuticle, where the likelihood of viable hyphae is the greatest. For proximal subungual onychomycosis, the normal surface of the nail plate is pared down with a no. 15 surgical blade at the lunula and the white debris is collected with a sharp curette from the deeper portion of the plate and the proximal nail bed. For WSO, the white spots on the nail are scraped and the outermost surface is discarded; the white debris directly underneath is then collected. For *Candida* infection, the material closest to the proximal and lateral nail edges should be obtained.

If *Candida* onycholysis is suspected, the lifted nail bed and, if necessary, the under surface of the nail plate are scraped. For TDO, any abnormal area of the nail plate or bed can be used as a specimen.

The sampled material can be divided into two portions: one for direct microscopy and the remainder for culture. If nail material is to be used, fine shavings or minute clippings are preferred to large pieces. The specimen should be obtained when the patient has been off both topical and systemic antifungal drugs for two to four weeks. If the specimen is shipped to an outside laboratory, a sterile container, a pill packet, a clean sheet of white paper folded and sealed with tape or a specially designed mailer such as a Dermapak™ can be used. Specimens must not be kept in moist media to avoid rapid multiplication of bacterial and fungal spores. Ideally nail specimens should be processed within a week, although infective fungal elements can remain viable for months after specimen collection.

Specimen analysis

Both direct microscopy and culture of sampled material are necessary to definitive identification of the aetiologic agent. Whereas direct microscopy serves only as a screening test for the presence or absence of fungi; culture can actually help in differentiating among the pathogens and identifying the aetiologic agent. The clinician should be aware of the limitations of direct microscopy in diagnosing the cause of onychomycosis. Direct microscopy is often time-consuming because nail debris is thick and coarse and hyphae are usually sparse and there also exists a possibility of false negative results at a rate of approximately 5 to 15%.^[20] The specimen can be mounted in a solution of 10 to 30% KOH or NaOH mixed with 5% glycerol, warmed to emulsify lipids and examined under 40x objective lens. An alternate formulation consists of 20% KOH and 36% DMSO.^[20] The specimen may be counterstained with chitin-specific chlorazol black E to accentuate hyphae. Furthermore, it will not stain potential contaminants such as cotton or elastic fibres, which eliminates many false-positive findings. Parker's blue-black ink also can be added to the KOH preparation to improve visualisation, but this stain is not chitin-specific. Calcofluor white, a fluorescent dye that stains chitin in the fungal cell wall, can be used to enhance a standard KOH preparation. However, the use of this stain is not always practical in a clinical setting because a fluorescent microscope is required. The nail is examined for fungal hyphae or arthrospore. In *Candida* infections, yeast forms are also present. In certain nondermatophyte infections conidia may be formed *in situ*. Culture is the only method by which

the causative microorganism can be identified. As nails are non-sterile; care should be taken with culture analysis as contaminants may obscure the actual pathogen.

Two different media are used for culturing nail specimens; primary medium (containing cycloheximide selective against most nondermatophytic molds and bacteria) such as dermatophyte test media (DTM), Mycosel (BBL) and Mycobiotic (DIFCO) and secondary medium (free of cycloheximide that allows isolation of nondermatophytes nail pathogens) such as Sabouraud glucose agar, Littman's oxgall medium and potato dextrose agar. The addition of antibiotics such as chloramphenicol and gentamicin to Sabouraud glucose agar or potato dextrose agar is an additional precaution to eliminate bacterial contamination from non-sterile sites. Ideally the specimen should be incubated at 25-30°C.

The incidence and clinical significance of other than dermatophytic fungi or moulds causing onychomycosis is unknown, because they may be colonising organisms rather than pathogens. Therefore, reference laboratories should provide data on whether the isolated fungus was a likely pathogen or an unlikely one. All dermatophytes should be considered pathogens.

To increase the predictive power of a diagnosis of dermatophytic invasion of a nail, Summerbell ^[21] suggested that non-filamentous non-dermatophytes identified in nail tissue may be considered as one of the following:

1. Contaminant (species growing in culture from dormant propagules on the nails)
2. Normal mammalian surface commensal organism
3. Transient saprobic coloniser (coloniser of accessible surface molecules but non invasive)
4. Persistent secondary coloniser (coloniser of material infected by a dermatophyte but incapable of remaining after the dermatophyte is eliminated)
5. Successional invader (species that can cause infection after gaining entry into a nail via the disruption caused by a primary pathogen)
6. Primary invader (able to infect and cause onychomycosis in a previously uncolonised nail)

As an additional confirmatory technique, definitive identification of non-dermatophytic invasion in nails may require the isolation of the agent from successive specimens from the infected region.

The difficulty in isolating fungi from nail clippings in cases of onychomycosis because of the non-viability of the fungal hyphae in the distal portion of the nail plate from where the scraping is done is well known. In order to improve the isolation rate various methods have been derived. These include the use of a grinder ^[22] or a dental drill fitted with a suction nozzle, ^[23] which

collects the nail dust for microscopy and culture. This latter instrument has raised the success rate of culture from microscopically positive nails from the usual reported rates of 50-75% to about 88%, but is not a practical procedure for the routine laboratory. ^[24]

If neither microscopy nor culture yields a diagnosis, histological analysis of pulverized nail plate clippings will determine whether the pathogen is a fungus. This procedure is helpful when the patient has a dystrophic nail that has repeatedly failed to show a positive response with potassium hydroxide or culture. Nail plate fragment can be sent in a 10% buffered formalin container for histopathologic analysis such as periodic acid-Schiff (PAS) staining. PAS stains glycogen and mucoproteins in the fungal cell wall. In one recent study, PAS was found to be more sensitive than KOH preparation and culture alone (92% versus 80% or 59% respectively) and PAS staining plus culture had the best sensitivity overall. ^[25] Another advantage of histopathologic evaluation with PAS is the short time required to render a diagnosis compared to culture. Histopathology reliably demonstrates whether a fungus is invasive or merely colonising subungual debris but like KOH this preparation does not identify the particular pathogen. PAS stain is usually sufficient to demonstrate fungi; however, small serum inclusions may be mistaken for fungi, as they are also PAS positive. The methenamine silver stain (Grocott) and calcofluor white are more selective. Nail biopsy is the last resort.

Treatment

As can be imagined, the treatment of onychomycosis has been attempted throughout the ages, but success has been limited until the current decade. In choosing therapy, the physician needs to consider the patient's age and health, the infecting organism, potential side effects and drug interactions of the various agents, the cost of treatment, the dosage schedule and patient compliance. As the rate of growth of toenails is one-third to one-half of fingernails, therapy of the former using the classical systemic drugs such as griseofulvin and ketoconazole must be continued for 12-18 months whereas fingernail infections may be cured in six months.

Oral griseofulvin and ketoconazole; once the agents of choice for the treatment of onychomycosis, have been superseded by newer systemic compounds that have a higher cure and lower relapse rates, cause fewer side effects and are suitable for short-term dosing. ^[26] Griseofulvin represented a promising advance in antifungal therapy when it first became available for clinical use nearly forty years ago. However, its effectiveness proved a disappointment, since its spectrum of activity is limited to dermatophytes and a prolonged duration of therapy is required for maximal efficacy—a period that may last for more than one year. Poor compliance with long-term therapy as a result of the side effects and the slow and incomplete clearance of dystrophic nails, led to success rates as low as 3-38%, with recurrence of infection often observed. ^[27]

Ketoconazole, developed in the 1980s, was the first orally active imidazole with a relatively broad spectrum of activity against dermatophytes, some yeast and several moulds. However, the long-term use of oral ketoconazole in onychomycosis, which is necessary to effect improvement or cure, is limited by the occurrence of side effects and significant drug interactions. ^[28]

The newer antifungal agents (itraconazole, fluconazole, terbinafine) block the ergosterol synthesis pathway at different points, a difference with implications for these drugs' efficacy and side effects.

Fluconazole, a triazole developed in the 1990s, is active against dermatophytes, *Candida* spp. and certain other fungi. Studies of fluconazole in onychomycosis show high cure rates but a need of long treatment time along with demonstration of some potentially significant drug interactions. ^[29]

Itraconazole, a broad-spectrum synthetic antifungal triazole approved in 1995 for the treatment of onychomycosis, represents an advancement beyond earlier therapies, due to its broad spectrum of activity, its high affinity for keratin and its pharmacokinetic profile. It is highly effective in the treatment of dermatophyte, yeast and some non-dermatophytic mould infections of the nails. Due to its rapid penetration into the nail and prolonged presence in the nail after discontinuation of drugs; Itraconazole has been evaluated in intermittent dosing or "pulse therapy" regimes which consists of dosing for one week (pulse) per month for a set number of months. ^[30]

The allylamine antifungal agent terbinafine is effective against dermatophytes and some moulds but has less activity in *C. albicans* infections. Results from several studies show that terbinafine has a high mycological cure rate and it significantly reduces treatment time over the older systemic agents. ^[31]

Regardless of which continuous oral antifungal agents the physician prescribes, a baseline liver profile and a blood chemistry study are recommended; however, this is not indicated for itraconazole pulse therapy.

Topical antifungal agents are of limited efficacy when used alone or with older antifungal agents to treat onychomycosis, but they may result in a more rapid cure when used in conjunction with the newer systemic compounds. They may also help to prevent the recurrence of tinea pedis, which often accompanies fungal toenail infections. Topical therapy has the greatest potential as primary therapy in mild infections, as palliative therapy in those unable to take oral therapy and as a prophylactic agent. Improvement of the conventional formulations led to the development of an alcoholic solution containing 28% tioconazole and undecylenic acid, for instance, which has produced moderate results. ^[32] A further step forward has been achieved with the development of new vehicles in the form of colourless nail lacquers known from cosmetic formulations. Two compounds, amorolfine and ciclopirox, are currently used in a lacquer base in several countries.

Surgical nail removal is not often used because of the discomfort, cost and possible cosmetic disfigurement. Avulsion of the nail combined with a topical antifungal agent, under occlusion, may be effective in selected patients. However, because of the inherent problems of nail avulsion, this is best limited to those with only one or two dystrophic nails and those intolerant of oral antifungals. Total surgical removal has to be discouraged: the distal nail bed may shrink and become dislocated dorsally. In addition, the loss of counter pressure produced by the removal of the nail plate allows expansion of the distal soft tissue and the distal edge of the regrowing nail

then embeds itself. This can be largely overcome by using partial nail avulsion. Chemical avulsion, done by urea ointment, is a painless method that has superseded partial surgical avulsion.

Preventing recurrence and relapse

Even with apparently optimal diagnosis and treatment, one in five onychomycosis patients are not cured by current therapies. The reasons for the 20% failure rate are inaccurate diagnosis, misidentification of the pathogen, presence of a second disorder, characteristics of the nails, presence of a high fungal inoculum and/or drug-resistant microorganisms, compromised immune system of the host, diabetes mellitus or peripheral vascular disease.

Following are some suggested measures:

1. Avoid going barefoot in public places
2. Keep feet cool and dry
3. Apply topical antifungal medication regularly to the feet and toe nails
4. Discard old shoes and "rest" shoes periodically to decrease their exposure to fungi
5. Apply an antifungal powder/spray to the inside of shoes once a week or more
6. Comply with the treatment protocol^[50]

Annexure 2

Annexure 2

Bharath Institute of Higher Education and Research

Sri Lakshmi Narayana Institute of Medical Sciences

Participant list of Value-added course: **ONYCHOMYCOSIS-DR09**

(Nov 2018 – Feb- 2019)

2 nd Year MBBS Student			
Sl. No	Name of the Student	Reg No	Signature
1	SOURABH DAS	U17MB381	<i>Sourabh Das</i>
2	SRIKAVYA .G	U17MB382	<i>Srikavya</i>
3	SRIшти SINGH	U17MB383	<i>Sriшти Singh</i>
4	SRITAMA SAHA	U17MB384	<i>Sritama Saha</i>
5	SUBHASHREE ABHIPSA GIRI	U17MB385	<i>Subhashree</i>
6	SUMAN KUMAR SAHOO	U17MB386	<i>Suman Kumar Sahoo</i>
7	SURVE BHUSHAN SUNIL	U17MB387	<i>Surve Bhushan</i>
8	SURVESH PODDAR	U17MB388	<i>Survesh Poddar</i>
9	SURYAWANSHI SIDDHANT AJAY	U17MB389	<i>Suryawanshi</i>
10	SYAMA SHAJEEV	U17MB390	<i>Syama Shajeev</i>
11	SACHI SHASTRI	U17MB371	<i>Sachi Shastri</i>
12	SHIVAM ANMOL	U17MB375	<i>Shivam Anmol</i>
13	SHIVANI BISWAL	U17MB376	<i>Shivani Biswal</i>
14	SHREYA KUMARI	U17MB377	<i>Shreya Kumari</i>
15	SHUBHAM KAMDE	U17MB378	<i>Shubham Kamde</i>

Buvanaratchagan
Dr. A. B. V. BUVANARATCHAGAN, MD.,
Reg. No. 1130
Asst. Professor, Dermatology
Sri Lakshmi Narayana Institute of Medical Sciences
Osudu, Kudapakkam, Puducherry-605 002
RESOURCE PERSON

PROFESSOR & HEAD
DEPT. OF DERMATOLOGY
SRI LAKSHMI NARAYANA INSTITUTE OF
MEDICAL SCIENCES
Harsha Vardhan KH.
OSUDU, PUDUCHERRY
Dr. K. Harsha Vardhan
COORDINATOR

ANNEXURE-3



SRI LAKSHMI NARAYANA INSTITUTE OF MEDICAL SCIENCES

ONYCHOMYCOSIS

MULTIPLE CHOICE QUESTIONS Annexure- III

ANSWER ALL QUESTIONS Course code: DR09

MULTIPLE CHOICE QUESTIONS

ANSWER ALL THE QUESTIONS

1. What is the most common pattern of onychomycosis.

- a) PSO
- b) Endonyx onychomycosis
- c) DLSO
- d) SO

2. The yeast that causes onychomycosis is:

- a) Aspergillus spp
- b) Fusarium spp
- c) Scopulariopsis brevicaulis
- d) Candida albicans

3. The organism that can invade nail plate easily and is the most common cause of onychomycosis is:

- a) T. rubrum
- b) T. interdigitale
- c) Fusarium
- d) T. soudanense

4. Two major clinical features of DLSO are:
- a) Subungual hyperkeratosis and nail thickening
 - b) Paronychia and pitting
 - c) Nail thickening and pitting
 - d) Subungual hyperkeratosis and paronychia

5. The 2nd most common clinical pattern of onychomycosis is:
- a) DLSO
 - b) SO
 - c) TDO
 - d) PSO

6. What is the definitive diagnostic test to find etiology of onychomycosis?
- a) Culture
 - b) Microscopy
 - c) Nail unit biopsy
 - d) PCR

7. What are the indications of oral treatment for onychomycosis?
- a) When multiple nails are involved
 - b) Lunula or matrix is involved
 - c) More than 75% of nail apparatus is involved
 - d) All of the above

8. What is the main clinical feature of non-dermatophyte onychomycosis?
- a) Subungual hyperkeratosis
 - b) Pitting
 - c) Nail thickening
 - d) Periungual inflammation

9. Which type of onychomycosis is related to AIDS and other immunocompromised conditions?
- a) DLSO
 - b) PSO
 - c) SO
 - d) Endonyx onychomycosis

10. A patient with onychomycosis is said to have developed relapse of the disease if he develops onychomycosis within how many months of starting the treatment?
- a) 6 months
 - b) 18 months
 - c) 12 months
 - d) 24 months

ANNEXURE-3



SRI LAKSHMI NARAYANA INSTITUTE OF
MEDICAL SCIENCES

ONYCHOMYCOSIS

SYAMA SHAJEEV

MULTIPLE CHOICE QUESTIONS Annexure- III

ANSWER ALL QUESTIONS Course code: DR09

MULTIPLE CHOICE QUESTIONS

ANSWER ALL THE QUESTIONS

1. What is the most common pattern of onychomycosis.

- a) PSO
- b) Endonyx onychomycosis
- c) DLSO
- d) SO

α

2. The yeast that causes onychomycosis is:

- a) Aspergillus spp
- b) Fusarium spp
- c) Scopulariopsis brevicaulis
- d) Candida albicans

α

3. The organism that can invade nail plate easily and is the most common cause of onychomycosis is:

- a) T. rubrum
- b) T. interdigitale
- c) Fusarium
- d) T. soudanense

—

4. Two major clinical feature of DLSO are:

- a) Subungual hyperkeratosis and nail thickening

β

8
10

Kardhan K.H.
5/9/17

- b) Paronychia and pitting
- c) Nail thickening and pitting
- d) Subungual hyperkeratosis and paronychia

5. The 2nd most common clinical pattern of onychomycosis is:

- a) DLSO
- b) SO
- c) TDO
- d) PSO

6. What is the definitive diagnostic test to find etiology of onychomycosis?

- a) Culture
- b) Microscopy
- c) Nail unit biopsy
- d) PCR

7. What are the indications of oral treatment for onychomycosis?

- a) When multiple nails are involved
- b) Lunula or matrix is involved
- c) More than 75% of nail apparatus is involved
- d) All of the above

8. What is the main clinical feature of non-dermatophyte onychomycosis?

- a) Subungual hyperkeratosis
- b) Pitting
- c) Nail thickening
- d) Periungual inflammation

9. Which type of onychomycosis is related to AIDS and other immunocompromised conditions?

- a) DLSO
- b) PSO
- c) SO
- d) Endonyx onychomycosis

10. A patient with onychomycosis is said to have developed relapse of the disease if he develops onychomycosis within how many months of starting the treatment?

- a) 6 months
- b) 18 months
- c) 12 months
- d) 24 months

ANNEXURE-3



SRI LAKSHMI NARAYANA INSTITUTE OF
MEDICAL SCIENCES

ONYCHOMYCOSIS

SOURABH
PAS

MULTIPLE CHOICE QUESTIONS

Annexure- III

ANSWER ALL QUESTIONS Course code: DR09

MULTIPLE CHOICE QUESTIONS

ANSWER ALL THE QUESTIONS

1. What is the most common pattern of onychomycosis.

- a) PSO
- b) ~~Endonyx~~ onychomycosis ✓
- c) DLSO
- d) SO

2. The yeast that causes onychomycosis is:

- a) Aspergillus spp
- b) ~~Fusarium~~ spp ✓
- c) Scopulariopsis brevicaulis
- d) Candida albicans

3. The organism that can invade nail plate easily and is the most common cause of onychomycosis is:

- a) ~~T. rubrum~~ ✓
- b) T. interdigitale
- c) Fusarium
- d) T. soudanense

4. Two major clinical feature of DLSO are:

- a) ~~Subungual hyperkeratosis~~ and nail thickening

9
10

Vardhan KH
5/9/12.

- b) Paronychia and pitting
- c) Nail thickening and pitting
- d) Subungual hyperkeratosis and paronychia

5. The 2nd most common clinical pattern of onychomycosis is:

- a) DLSSO
- ~~b) SO~~
- c) TDO ✓
- d) PSO

6. What is the definitive diagnostic test to find etiology of onychomycosis?

- ~~a) Culture~~
- b) Microscopy ✓
- c) Nail unit biopsy
- d) PCR

7. What are the indications of oral treatment for onychomycosis?

- a) When multiple nails are involved
- b) Lunula or matrix is involved
- c) More than 75% of nail apparatus is involved ✓
- ~~d) All of the above~~

8. What is the main clinical feature of non-dermatophyte onychomycosis?

- a) Subungual hyperkeratosis
- b) Pitting ✓
- ~~c) Nail thickening~~
- d) Periungual inflammation

9. Which type of onychomycosis is related to AIDS and other immunocompromised conditions?

- a) DLSSO
- ~~b) PSO~~ ✓
- c) SO
- d) Endonyx onychomycosis

10. A patient with onychomycosis is said to have developed relapse of the disease if he develops onychomycosis within how many months of starting the treatment?

- a) 6 months
- b) 18 months
- ~~c) 12 months~~ ✓
- d) 24 months

ANNEXURE-4
Student Feedback Form

Course Name: **ONYCHOMYCOSIS**

Subject Code: **DR09**

Name of Student: _____ Roll No.: _____

We are constantly looking to improve our classes and deliver the best training to you. Your evaluations, comments and suggestions will help us to improve our performance

SI. NO	Particulars	1	2	3	4	5
1	Objective of the course is clear					
2	Course contents met with your expectations					
3	Lecturer sequence was well planned					
4	Lectures were clear and easy to understand					
5	Teaching aids were effective					
6	Instructors encourage interaction and were helpful					
7	The level of the course					
8	Overall rating of the course	1	2	3	4	5

** Rating: 5 – Outstanding; 4 - Excellent; 3 – Good; 2– Satisfactory; 1 - Not-Satisfactory*

Suggestions if any:

Date: 20-02-2019

Signature

ANNEXURE-4
Student Feedback Form

Course Name: **ONYCHOMYCOSIS**

Subject Code: **DR09**

Name of Student: Syama Roll No.: U17MB390
SPADIEV


We are constantly looking to improve our classes and deliver the best training to you. Your evaluations, comments and suggestions will help us to improve our performance

SI. NO	Particulars	1	2	3	4	5
1	Objective of the course is clear	✓				
2	Course contents met with your expectations		✓			
3	Lecturer sequence was well planned			✓		
4	Lectures were clear and easy to understand			✓		
5	Teaching aids were effective				✓	
6	Instructors encourage interaction and were helpful			✓		
7	The level of the course			✓	✓	
8	Overall rating of the course	1	2	3	4	5

* Rating: 5 - Outstanding; 4 - Excellent; 3 - Good; 2 - Satisfactory; 1 - Not-Satisfactory

Suggestions if any:

Date: 20-02-2019


Signature

ANNEXURE-4
Student Feedback Form

Course Name: **ONYCHOMYCOSIS**

Subject Code: **DR09**


Name of Student: SOURABH DAS Roll No.: U17MB387

We are constantly looking to improve our classes and deliver the best training to you. Your evaluations, comments and suggestions will help us to improve our performance

Sl. NO	Particulars	1	2	3	4	5
1	Objective of the course is clear	✓				
2	Course contents met with your expectations		✓			
3	Lecturer sequence was well planned		✓			
4	Lectures were clear and easy to understand			✓		
5	Teaching aids were effective				✓	
6	Instructors encourage interaction and were helpful				✓	
7	The level of the course			✓		
8	Overall rating of the course	1	2	3	4	5

* Rating: 5 - Outstanding; 4 - Excellent; 3 - Good; 2 - Satisfactory; 1 - Not-Satisfactory

Suggestions if any:


Signature

Date: 20-02-2019



Sri Lakshmi Narayana Institute of Medical Sciences

Affiliated to Bharath Institute of Higher Education & Research

(Deemed to be University under section 3 of the UGC Act 1956)



CERTIFICATE OF MERIT

This is to certify that SHAMSHAJEEV has actively participated in the Value

Added Course on *Onychomycosis- Overview* held during Nov 2018 - Feb 2019 Organized by

Sri Lakshmi Narayana Institute of Medical Sciences, Pondicherry- 605 502, India.

Dr. A. BUVANARATCHAGAN, MD.,
Asso. Professor, Dermatology
Sri Lakshmi Narayana Institute of Medical Sciences
Pondicherry-605 502.

Dr. Buvanaratchagan

RESOURCE PERSON

ASSOCIATE PROFESSOR & HEAD
DEPT. OF DERMATOLOGY
SRI LAKSHMI NARAYANA
INSTITUTE OF MEDICAL SCIENCES
PONDICHERRY

Dr. K. Harsha Vardhan

COORDINATOR



Sri Lakshmi Narayana Institute of Medical Sciences

Affiliated to Bharath Institute of Higher Education & Research
(Deemed to be University under section 3 of the UGC Act 1956)





CERTIFICATE OF MERIT

This is to certify that SOUREASH DAS has actively participated in the Value

Added Course on *Onychomycosis- Overview* held during Nov 2018 - Feb 2019 Organized by

Sri Lakshmi Narayana Institute of Medical Sciences, Pondicherry- 605 502, India.


Dr. Buvanaratchagan
Assoc. Professor, Dermatology
Sri Lakshmi Narayana Institute of Medical Sciences
Pondicherry-605 502
RESOURCE PERSON


PROFESSOR & HEAD
DEPT. OF DERMATOLOGY
SRI LAKSHMI NARAYANA
INSTITUTE OF MEDICAL SCIENCES
Dr. K. Harisha Vardhan
OSURU, PONDICHERY
COORDINATOR

Course completion letter

Date 25-02-19

From
Dr. K. Harsha Vardhan
Department of Dermatology
Sri Lakshmi Narayana Institute of Medical Sciences
Bharath Institute of Higher Education and Research
Chennai.

Through Proper Channel

To
The Dean
Sri Lakshmi Narayana Institute of Medical Sciences
Bharath Institute of Higher Education and Research,
Chennai.

Sub: Completion of value-added course: Onychomycosis

Dear Sir,

With reference to the subject mentioned above, the department has conducted the value-added course titled: **Onychomycosis** on 20-12-2018. We solicit your kind action to send certificates for the participants, that is attached with this letter. Also, I am attaching the photographs captured during the conduct of the course.

Kind Regards

Dr. K. Harsha Vardhan

<HOD Sign and Seal>

Encl: Certificates

Photographs

Course completion letter

Date 25-02-19

From
Dr. K. Harsha Vardhan
Department of Dermatology
Sri Lakshmi Narayana Institute of Medical Sciences
Bharath Institute of Higher Education and Research
Chennai.

Through Proper Channel

To
The Dean
Sri Lakshmi Narayana Institute of Medical Sciences
Bharath Institute of Higher Education and Research,
Chennai.


Sub: Completion of value-added course: Onychomycosis

Dear Sir,

With reference to the subject mentioned above, the department has conducted the value-added course titled: **Onychomycosis** on 20-12-2018. We solicit your kind action to send certificates for the participants, that is attached with this letter. Also, I am attaching the photographs captured during the conduct of the course.

Kind Regards

Dr. K. Harsha Vardhan


<HOD Sign and Seal>
PROFESSOR & HEAD
DEPT. OF DERMATOLOGY
SRI LAKSHMI NARAYANA INSTITUTE OF
MEDICAL SCIENCES
MUDUCHERRY.

Encl: **Certificates**

Photographs

